

# CARPHOLOGY by A Fo Ben



Pract Neurol 2010; 10: 310

## Inter-ictal psychosis: who's at risk?

How distinct is inter-ictal psychosis from schizophrenic psychosis? A Japanese study of 285 adults with epilepsy and interictal psychosis showed psychosis beginning a mean of 14 years after epilepsy onset—earlier in those with generalised epilepsy, those with a psychosis family history, and those without learning difficulties. Temporal lobe cortex structural changes are well recognised in schizophrenia; similar changes were evident here in those at highest risk of psychosis. Seizure frequency is notoriously difficult to quantify but these findings suggest that personal vulnerabilities (and possibly seizure related damage) are more important than long epilepsy duration.

*Br J Psychiatry* 2010;**196**:212–16. <http://bjp.rcpsych.org/cgi/reprint/196/3/212>

## Suicide and antiepileptic drugs

Attempted or completed suicide while on antiepileptic drugs is thankfully rare—1.9 per 1000 patient years. The US Food and Drug Administration warned in 2008 that antiepileptic drugs may increase the risk of suicidal thoughts but not of completed suicide. Their meta-analysis showed

topiramate was the drug most associated with suicide (40 events in 7742 participants taking the drug), odds ratio 2.53 (95% confidence interval 1.21 to 5.85) compared with placebo). Thus a *JAMA* paper suggesting topiramate is the drug least associated with suicidal thoughts must be read with caution. Over a third of patients in the *JAMA* study took topiramate for migraine and were more likely to be female (a protective factor for completed suicide).

*JAMA* 2010;**303**:1401–9. <http://www.fda.gov/ohrms/dockets/ac/08/briefing/2008-4372b1-01-FDA.pdf>

## Chronic fatigue: listening is not enough

Patients with chronic fatigue need more effective interventions. In a single blind, randomised, controlled trial, 296 patients with chronic fatigue syndrome received pragmatic (graded activity) rehabilitation, supportive listening or usual treatment. Nurses delivered the interventions at home over 18 weeks. The benefits of pragmatic rehabilitation seen at 20 weeks were no longer apparent at 70 weeks (using the Chalder fatigue scale and SF-36 physical functioning scales): effect estimate at 20 weeks –1.18,  $p=0.021$ . Supportive listening helped

not at all. Nurse led domiciliary pragmatic rehabilitation is therefore reasonable but established chronic fatigue seems to require longer term treatment.

*BMJ* 2010;**340**:c1777.

## Cords need copper

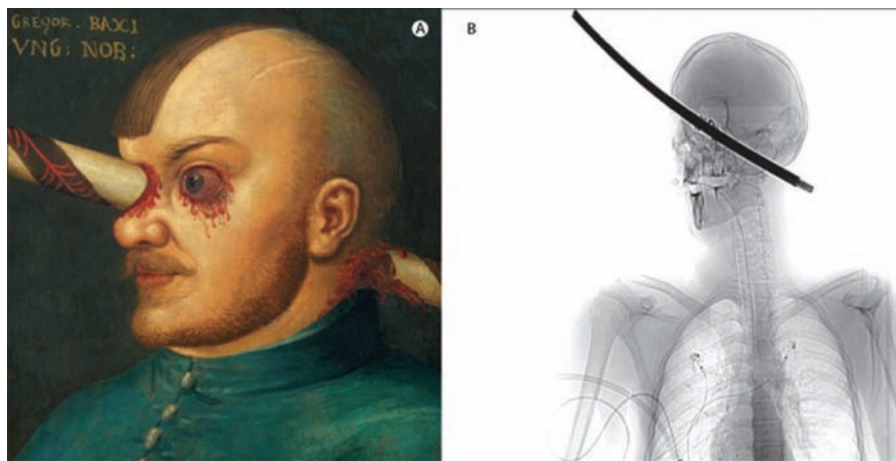
A *BMJ Lesson of the Week* reminds us that patients with subacute combined degeneration of the cord but normal serum  $B_{12}$  levels may have copper deficiency. Copper deficient sensory ataxia has been recognised for decades as 'swayback disease' in ruminant animals. Although frequently overlooked in humans, potential causes include previous gastric surgery, malabsorption, hyperzincaemia and possibly cola drinking. An identical diagnostic oversight decorates a case collection of ways that neurologists miss diagnoses (*Ann Neurol* 2010;**67**:425–33). If we have recently correctly diagnosed a rare condition we are more likely to diagnose it again when faced with a similar history—the 'availability heuristic'—even if other evidence is against it. So having recently correctly diagnosed vitamin  $B_{12}$  deficiency, a neurologist might diagnose this again when presented with a similar case (rather than copper deficiency), despite a normal serum  $B_{12}$  level.

*BMJ* 2010;**340**:c508.

## An eye for detail

The possible truth of the legend of the hussar Gregor Baci (figure) who allegedly survived an impaled lance in the head and neck, has recently gained support. A craftsman with an almost identical injury from a metal bar (figure B), fittingly also in Austria, survived without serious physiological dysfunction (although benefitting from its surgical removal).

*Lancet* 2010;**375**:317.



**Figure**

(A) Anonymous artist. Gregor Baci, c. 1500 (Kunsthistorisches Museum, Austria). (B) CT scan of the patient (posterior–anterior scout view, approximately semilateral view of the head). Reprinted from *Lancet* 2010;**375**:317. Missmann M *et al*. Impaled head. Copyright 2010, with permission from Elsevier.

A Fo Ben is always on the lookout for suitable Carphology titbits and comments on what has been included. Email the editor-in-chief if you come across anything.